

Multiple hepatic arterial injections of recombinant adenovirus p53 and 5-fluorouracil after transcatheter arterial chemoembolization for unresectable hepatocellular carcinoma: a pilot phase II trial

Anti-Cancer Drugs 2009, 20:389–395

Geng Tian, Jiliang Liu, Jie Sui, Ruming Zhou and Weihong Chen

Departments of aTumor, bRadiology and cHematology, Institute of Hematology, Shenzhen Second People's Hospital, South Medical University, Shenzhen, China
e-mail: gengtian71@yahoo.com.cn

This pilot phase II study was designed to determine the efficacy, toxicities, and biological activity of multiple hepatic arterial injections of recombinant adenovirus p53 (rAd-p53) and 5-fluorouracil (5-FU) after transcatheter arterial chemoembolization (TACE) when compared with TACE alone in patients with unresectable hepatocellular carcinoma (HCC). Forty-six patients with unresectable HCC were randomized in either group 1 [23 patients, multiple hepatic arterial injections of Ad-p53 (1×10^{12} viral particles) and 5-FU (500–750 mg), after TACE] or group 2 (23 patients, TACE alone). In group 1, the number of Ad-p53/5-FU courses administered was 166 (median 7, range 3–12). In group 2, the number of TACE courses administered was 47 (median 2, range 1–3). Partial response and stable disease were 69.5% in group 1 and 65.2% in group 2. Times to progression were 9.6 months (range 2.1–21.7) in group 1 and 8.3 months (range 2.1–16.8) in group 2. Overall survivals were 12.8 months (range 2.7–26.2) in group 1 and 10.4 months (range 2.7–22.5) in group 2. Toxicities in both groups were generally mild and reversible. The most common Ad-p53-related toxicity was a transient fever. Specific p53 transgene expression was detected using reversetranscriptase polymerase chain reaction in biopsied tumor tissues. Distribution studies revealed that the vector was detected in the plasma, but rarely in the gargle and urine. This study shows that multiple hepatic arterial injections of Ad-p53 and 5-FU after TACE can be active and safe as a treatment for patients with unresectable HCC

Keywords: chemotherapy, gene therapy, hepatocellular carcinoma, p53 gene, transcatheter arterial chemoembolization

Introduction

Hepatocellular carcinoma (HCC) is one of the most common malignancies in the world. Globally, it ranks fifth among the most common cancers but is the third leading cause of cancer death, with an estimate of more than 500 000 new cases each year [1–3]. Geographically, HCC prevails in areas such as southeast Asia and sub-Saharan Africa where hepatitis infection is endemic. Chronic hepatitis B infection, hepatitis B virus carrier status, and to a lesser degree hepatitis C infection are important

etiological factors of HCC [4]. Integration of viral DNA into the genome with consequent inactivation of the p53 gene is involved in hepatocarcinogenesis [5].

HCC is a highly lethal cancer that typically has a poor prognosis. To date, surgical approaches, including liver resection and liver transplantation, are regarded potentially as curative treatments for HCC, particularly in patients with small and noninvasive tumors [6]. However, in most patients the tumors are not suitable for surgical treatment because of multicentric tumors, extrahepatic metastases, early vascular invasion, shortage of donor organs, high complication rates, and comorbidities [7]. Transcatheter arterial chemoembolization (TACE) has become the standard treatment for unresectable HCC but this method is often unsuccessful [8].

Genetic abnormalities seen in HCC tumor cells include inactivation of tumor suppressor genes and activation of oncogenes [9, 10]. The tumor suppressor gene of most interest is p53, which is located on the short arm of chromosome 17 (17p13). Deletions or mutations of wildtype p53 have been identified in approximately 50% of all tumor types. In HCC, the incidence of the p53 mutation was reported to be 61% and its presence in HCC indicates a poorer prognosis [11, 12]. Inactivity of p53 results in an impaired cellular response to various stresses, including DNA damage, growth factor withdrawal, and oncogenic transformation as well as genomic instability [13]. Moreover, p53 loss may also abrogate an effective apoptotic response to chemotherapy or radiation treatment [14,15].

Extensive basic research on the p53 gene facilitated its clinical application [16–18]. Encouraging clinical responses to adenovirus p53 (Ad-p53) as a single agent or combined with radiotherapy or chemotherapy have been reported by a number of study groups, including head and neck squamous cell carcinoma, glioma, nonsmall-cell lung cancer, and bladder carcinoma [19–22]. In a recently published study, Ad-p53 (Gendicine, Shenzhen SiBiono GenTech, China) in combination with TACE was superior to TACE alone in patients with advanced HCC in terms of tumor response, Karnofsky performance status, and survival [23]. We conducted a pilot phase II study to examine the efficacy and toxicities of multiple hepatic arterial injections of Ad-p53 (Gendicine) and 5-fluorouracil (5-FU) after TACE in the treatment of unresectable HCC. The biological activity and the pharmacokinetics of Ad-p53 were also determined in this study.

Materials and methods

Patient eligibility

Patients who met the following criteria were included: between 20 and 75 years of age; histologically confirmed HCC, unresectable or refractory to standard therapies, unresectable or refractory to standard therapies, such as percutaneous ethanol injection (PEI), operation, TACE, radiofrequency ablation (RF), or chemotherapy; Eastern Cooperative Oncology Group performance status of 0 or 1; no main portal vein involvement or extrahepatic metastasis; life expectancy greater than 12 weeks;

adequate bone marrow, liver, and renal function; and written informed consent from the patient. This protocol was approved by the Scientific and Ethics Committee of Shenzhen Second People's Hospital of South Medical University with the provisions of the Declaration of Helsinki and local laws and regulations.

Adenovirus

The Ad-p53 injection used was Gendicine (Shenzhen SiBiono GenTech). Gendicine is a recombinant human serotype 5 adenovirus in which the E1 region is replaced by a human wild-type p53 expression cassette. Gendicine was stored at -20°C at a concentration of 1×10^{12} viral particles/ampoule, and was thawed and diluted in 5 ml physiological saline solution for injection at room temperature within 30min before administration.

Treatment

Patients were divided into two groups randomly. For group 1, patients were treated by multiple hepatic arterial injections of recombinant adenovirus p53/5-FU after TACE through implanted port-catheter system (PCS). For group 2, patients were treated by TACE alone.

Transcatheter arterial chemoembolization was performed by the Seldinger technique and through femoral artery access in all patients. Diagnostic hepatic angiography confirmed tumor blush in all cases before chemotherapy delivery and embolization. Diagnostic angiography was performed to document portal vein patency before embolization. An emulsion of lipiodol (10 ml), doxorubicin (10–30 mg), mitomycin C (10–20 mg), and 5-FU (500–750 mg) was used for chemoembolization. For group 2, TACE was repeated every 6–12 weeks and was performed up to a maximum of three courses if the patient was eligible.

For the patients of group 1, after TACE, an arterial indwelling catheter was introduced with its tip placed in the hepatic artery and its end subcutaneously connected to a port embedded in the right iliac fossa. Five days after implanting PCS, Ad-p53 (1×10^{12} viral particles) followed by 5-FU (500–750 mg) were injected into the hepatic artery through PCS within 2 min every 5–7 days. There was an interval of 4–8 weeks between every four courses of injection. PCS was filled with heparinized saline (100U/ml) after each injection.

Toxicity and response criteria

Patients were monitored with regard to safety and tolerability according to the National Cancer Institute's Common Toxicity Criteria (version 2) for a minimum of 12 months or until death. Lesions were measured serially by radiographic scanning, and patients underwent biopsy for histology and molecular analyses. Tumor responses were determined with the use of the revised World Health Organization criteria (Response Evaluation Criteria in Solid Tumors). Liver function tests (LFTs) were assessed according to the following criteria: a minimal rise in liver enzyme levels was

considered to be an elevation of more than 10 U/ml after treatment; a mild rise in liver enzymes to be more than 20 U/ml after treatment; and a severe rise to be more than 100 U/ml after treatment.

Analysis of tumor biopsy tissues

For the patients of group 1, tumor biopsy samples were obtained by core biopsies of the tumor pretreatment and 48 h after the first, the fourth, the eighth, and the twelfth injection. Tissue samples were used for conventional reverse-transcriptase polymerase chain reaction (RT-PCR) assay to detect the expression of exogenous p53. Total RNA was isolated from biopsy samples and used as a template. After RT, a PCR procedure was used, with vector-specific primers. mRNA copy numbers of exogenous p53, p21, p53AIP1, BAK were also determined by real-time quantitative RT-PCR. Total RNA was used as a relative standard and human glyceraldehyde-3-phosphate dehydrogenase gene served as an internal control for relative mRNA amount. Real-time PCR was performed in the ABI Prism 7700 Sequence Detection System (PE Biosystems, Foster City, California, USA) according to the manufacturer's protocol.

Detection of adenoviral-specific antibodies by enzyme-linked immunosorbent assay

For the patients of group 1, the levels of antiadenovirus antibodies were evaluated in enzyme-linked immunosorbent assay (ELISA) using at least four serial dilutions. Internal controls provided by the manufacturers were used to establish a 'cutoff' level. Samples were always assayed in duplicate. The absorbance was read on a spectrophotometer at a wavelength of 450nm against a reference filter of 620 nm to compensate for differences in the material of the microtiter plate. Adenovirus IgG ELISA kit was product of Immuno-Biological Laboratories (IBL, Hamburg, Germany).

Vector dissemination and biodistribution analyses

For the patients of group 1, Ad-p53 shedding was monitored in the gargle, urine, and plasma specimens by a vectorspecific DNA-PCR assay. DNA was isolated from samples and analyzed for the presence of vector DNA by PCR. The PCR product crosses a p53 open-reading-frame/adenoviral DNA junction and is therefore specific for the Ad-p53 vector.

Statistical analysis

Patient disease characteristics and baseline laboratory values were compared using an independent sample t (not assuming equal variance), Mann-Whitney, or the Fisher's exact test as necessary. Differences of response to therapy were tested using Mann-Whitney U-test. Overall survival (OS) and time to progression (TTP) were calculated using survival analysis by the Kaplan-Meier method and compared using the log-rank test.

Results

Patient characteristics and treatment

Between October 2004 and February 2007, a total of 46 patients (23 in group 1 and 23 in group 2) were entered in the study (Table 1). There were no statistical differences among baseline characteristics between the two groups. Eleven patients of group 1 had failed prior conventional therapies including PEI (three patients), operation (two patients), TACE (two patients), RF (two patients), chemotherapy (one patient), and operation and radio-frequency ablation (one patient). p53 mutation was detected by immunohistochemistry in 11 patients of group 1. Among the 23 patients of group 1, 166 courses (mean, 7 courses/patient; range 3–12 courses/patient) of injection of Ad-p53/5-FU were administered. Eight patients of group 2 had failed prior conventional therapies including PEI (three patients), operation (two patients), RF (two patients), and TACE (one patient). In group 2, three patients (26.1%) received one course of TACE, 16 patients (56.5%) received two courses, and 4 (17.4%) patients received three courses TACE.

Clinical outcome

All patients were assessable for response with computed tomography (CT) scan and clinical findings. Responses of group 1 were as follows: five (21.7%) achieved PR and 11 (47.8%) had SD (Z16 weeks) (Table 2). Responses of TACE group were as follows: three (21.7%) achieved PR, and 10 (43.5%) had SD (Z16 weeks) (Table 2). There was no difference in overall response rates noted between the two groups (Table 2, $P=0.419$). With a median follow-up of 12.8 months, median TTP was 9.6 months (range 2.1–21.7 months) in group 1 and 8.3 months (range 2.1–16.8 months) in group 2 (Fig. 1). Median OS was 12.8 months (range 2.7–26.2 months) in group 1 and 10.4 months (range 2.7–22.5 months) in group 2 (Fig. 2). There were no statistically significant differences noted in TTP (log-rank $P=0.62$, Fig. 1) and OS (log-rank $P=0.87$, Fig. 2) between the two groups.

Table 1 Patient characteristics

Characteristics	TACE + rAd-p53/ 5-FU group (n = 23)		TACE group (n = 23)		P
	No.	%	No.	%	
Sex					0.475
Male	17	74	19	83	
Female	6	26	4	27	
Age (years)					0.256
Median	55		56		
Range	32–76		33–71		
ECOG performance status					0.501
0	16	70	18	78	
1	7	30	5	22	
Child–Pugh status					0.743
A	16	70	17	74	
B	7	30	6	26	
AFP (ng/ml)					0.729
> 400	17	74	18	80	
≤ 400	6	26	5	20	
Positive hepatitis status					0.550
Hepatitis B	20	87	21	91	
Hepatitis C	2	9	1	4	
Previous therapy					
PEI	3	13	3	13	
Operation	2	9	2	9	
TACE	2	9	1	4	
RF	2	9	2	9	
Chemotherapy	1	4			
Operation and RF	1	4			

5FU, 5-fluorouracil; AFP, α -fetoprotein; ECOG, Eastern Cooperative Oncology Group; IHC, immunohistochemistry; PEI, percutaneous ethanol injection; rAd-p53, recombinant adenovirus p53; RF, radio-frequency ablation; TACE, transcatheter arterial chemoembolization.

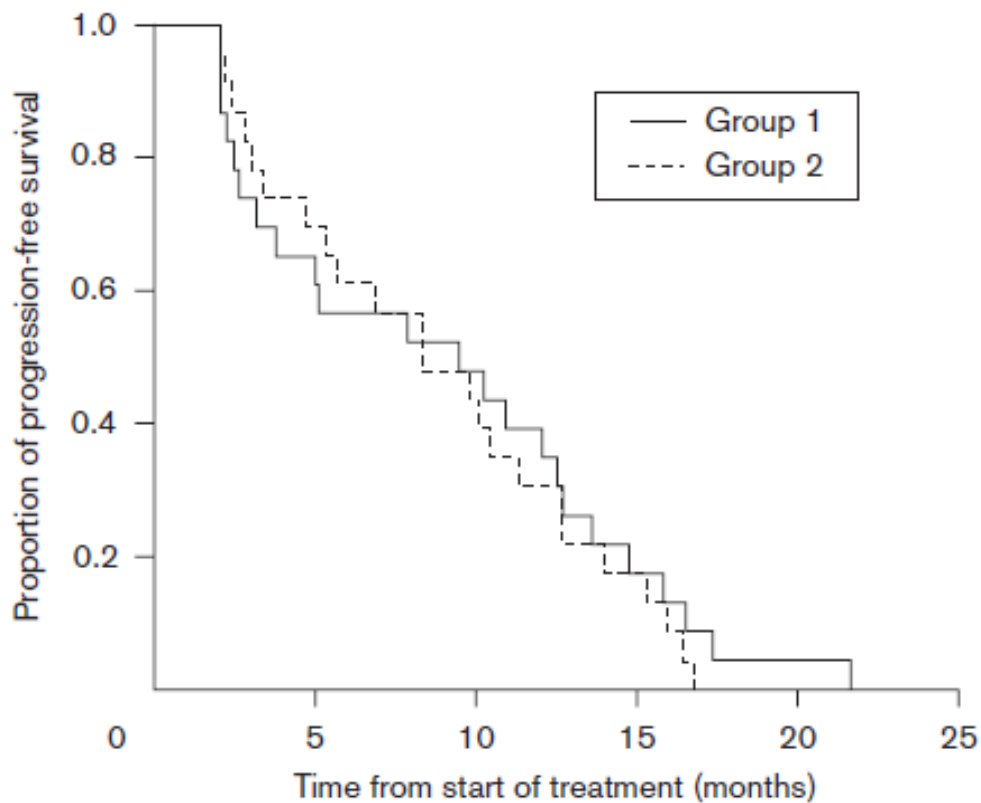
Table 2 Tumor response

Response	TACE + rAd-p53/5-FU (n = 23)		TACE (n = 23)	
	No.	%	No.	%
Partial response	5	21.7	5	21.7
Stable disease	12	52.2	11	47.8
Progressive disease	6	26.1	7	30.5

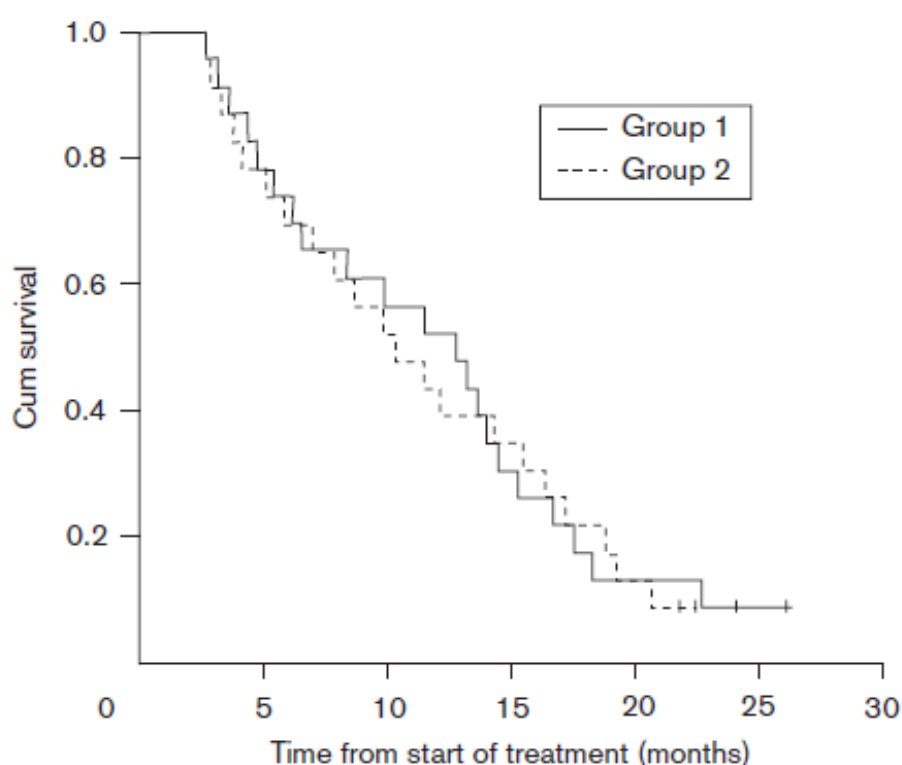
To be classified as stable disease, patients needed to have stable disease for ≥ 16 weeks.

5FU, 5-fluorouracil; rAd-p53, recombinant adenovirus p53; TACE, transcatheter arterial chemoembolization.

Fig. 1



Kaplan–Meier estimates of times to progression according to whether patients were randomly assigned to group 1 [multiple hepatic arterial injections of recombinant adenovirus p53 and 5-fluorouracil following transcatheter arterial chemoembolization (TACE)] or group 2 (TACE alone). Median survivals were 9.6 months in group 1 and 8.3 months in group 2.

Fig. 2

Kaplan–Meier estimates of overall survival according to whether patients were randomly assigned to group 1 [multiple hepatic arterial injections of recombinant adenovirus p53 and 5-fluorouracil following transcatheter arterial chemoembolization (TACE)] or group 2 (TACE alone). Median survivals were 12.8 months in group 1 and 10.4 months in group 2.

Table 3 Toxicity and complications of Gendicine and 5-fluorouracil injections^a

Toxicity	Number of injections	Grade 1 (%)	Grade 2 (%)	Grade 3 (%)	Grade 4 (%)	Total (%)
Fever	166	52 (31)	31 (19)	9 (5)	3 (2)	95 (57)
Nausea	166	22 (13)	8 (5)	0	0	30 (18)
Fatigue	166	15 (9)	5 (3)	0	0	20 (12)
Vomiting	166	5 (3)	2 (1)	0	0	7 (4)
Leukopenia	166	4 (2)	0	0	0	4 (2)
Anemia	166	2 (1)	1 (1)	0	0	3 (2)

^aShenzhen SiBiono GenTech, Shenzhen, China.

Toxicity and complications

Complications of TACE in all patients included pain, nausea, fever, vomiting, and fatigue. All of these complications were transient and mild. There were no statistically

significant differences noted in complications of TACE between the two groups (data not show). Toxicities and complications that occurred in all patients of group 1 are presented in Table 3. The most frequent vector-related complication was a transient fever (57%), with a highest reported grade of 4 occurring three times in one patient. In most patients, fever developed 3–24h after Ad-p53/5-FU injection. Fever under 39°C was a selflimited course. Fevers higher than 39°C were treated with cold foment or anileridine (2 ml) intramuscular. Patients generally recovered within 48 h. Other complications included nausea (18%), fatigue (12%), and vomiting (4%). All of these complications were transient and mild. Hematologic toxicity was limited, with four incidences of grade 1 leukopenia (2%) and three incidences of grade 1 or 2 anemia (2%). There was no increase in adverse events with multiple injections of Ad-p53/5-FU. Assessment of LFTs revealed no significant rise in liver enzymes or marked effect on LFTs (prothrombin time, bilirubin, albumin) in patients receiving Ad-p53/5-FU. Three patients had a mild rise in aspartate aminotransferase level and three patients had a minimal rise in bilirubin.

Antiadenoviral antibody studies

The presence of Ad-specific antibody levels was evaluated by ELISA before Ad-p53 treatment in 14 patients of group 1. All patients showed Ad-specific antibodies. Eight of these patients were also evaluated for Ad-specific antibodies at 5 days after their fourth injection. Antibody levels increased by a mean of $56.8 \pm 15.5\%$ after treatment, consistent with other trials [24, 25]. No relationship between response and Ad-specific antibodies (either pretreatment level or posttreatment increase) was observed.

Vector shedding and biodistribution

Gargle and urine samples of patients in group 1 were collected just before vector injection and daily for 5 days after the first injection. Excretion of Ad-p53 DNA from bodily secretions was rare. Only one sample of 30 serial gargle samples obtained from six patients and one sample of 23 serial urine samples obtained from five patients were positive. The presence of Ad-p53 was assayed in the plasma obtained before and 1, 2, and at 24h after the first vector injection. In all eight patients tested, vector was detected in plasma 1 and 2 h after injection by the DNA-PCR, and negative at 24h after injection.

Molecular analysis of tumor biopsy tissues

Tumor biopsy samples of 15 patients obtained before and 48 h after vector injection in group 1 were assessed for p53 mRNA expression by RT-PCR analysis using vector-specific primers (Table 4). All pretreatment samples were negative for p53 transgene expression because the primers can distinguish exogenous wt-p53 from preexisting mutant p53 in tumor samples. Vectorspecific p53 mRNA expression was detectable in 12 of 15 patients (80%) after the first vector injection, and in 8 of 11 patients (72.7%) after the fourth vector injection. Overall, all 15 patients showed positive p53 transgene expression during the treatment. To evaluate the biological

activity of Ad-p53-induced p53 expression, we performed quantitative analysis of p53-targeted gene expression by a real-time RT-PCR method. Paired biopsy samples obtained before and 48 h after the first injection were analyzed in patients 6 and 15 for the expression of exogenous p53, p21, BAK, and p53AIP1 mRNAs. We found that apoptosis-related gene expression such as p21, and p53AIP1 was higher in postinjection samples than that in preinjection biopsies (Fig. 3). The expression patterns of these mRNAs almost paralleled that of exogenous p53. In contrast, BAK expression pattern varied in patient 6.

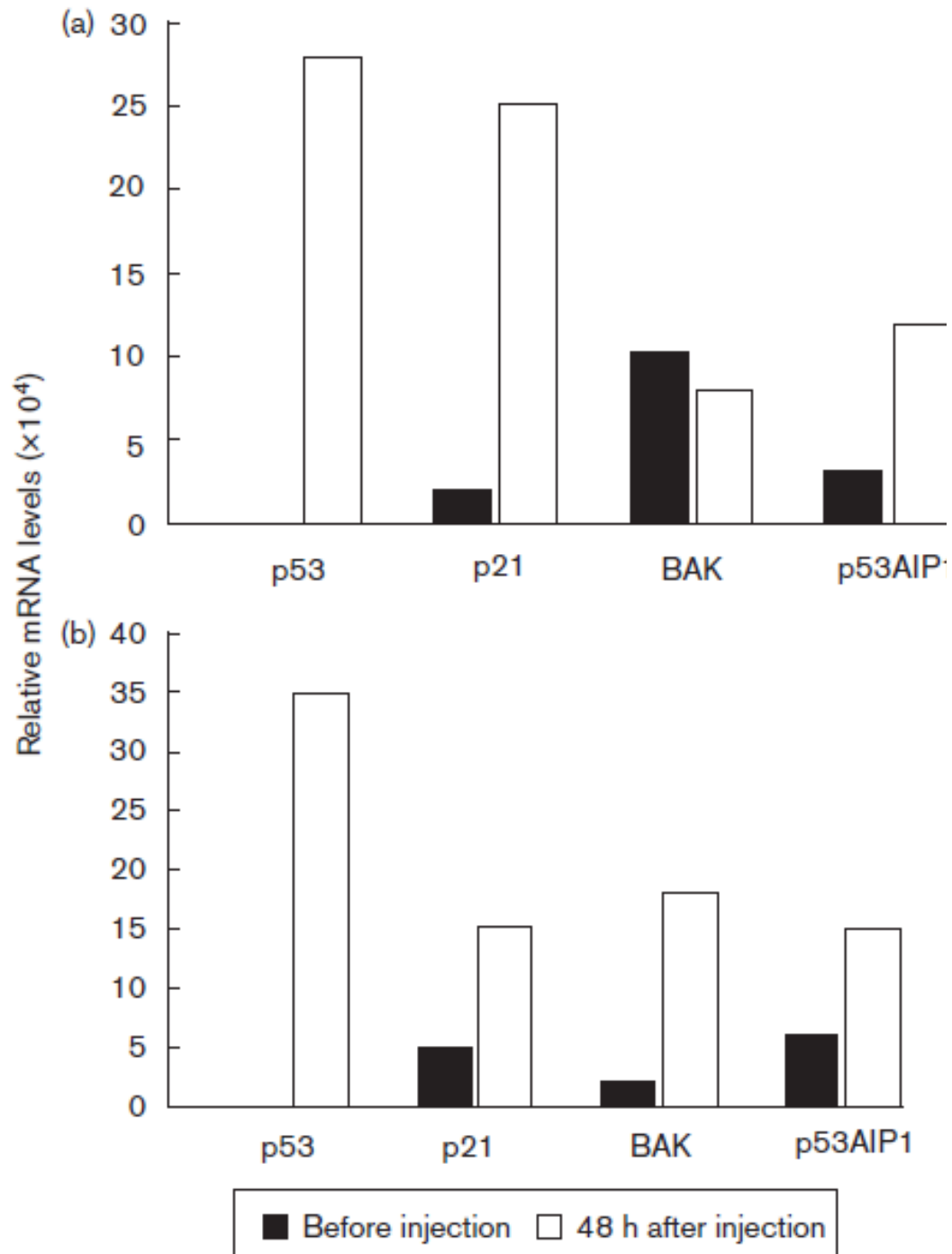
Table 4 Vector-specific p53 mRNA expression in tumor tissues 48 h after Gencidine and 5-fluorouracil injections^a

Patient no.	RT-PCR results course				
	Pretreatment	After the first injection	After the fourth injection	After the eighth injection	After the twelfth injection
1	-	+	-	+	
2	-	+	+	-	
3	-	+	-		
5	-	+	+		
6	-	+	-	+	+
8	-	+			
9	-	-	+		
11	-	+	+		
12	-	+			
15	-	+	+		
16	-	+	+	+	+
18	-	-	+		
19	-	+			
20	-	-	+		
22	-	+			

RT-PCR, reverse-transcriptase PCR.

^aShenzhen SiBiono GenTech, Shenzhen, China.

Fig. 3



Expression of exogenous p53 mRNA and p53-targeted gene mRNAs (p21, BAK, and p53AIP1) was measured by the real-time quantitative polymerase chain reaction assay. Tumor biopsy samples were obtained before and 48 h after the first injection of Gencidine and 5-fluorouracil in patients 6 (a) and 15 (b). All expression levels were normalized to that of human glyceraldehyde-3-phosphate dehydrogenase.

Discussion

HCC is a highly resistant solid tumor, and HCC cells are known to express the multidrug-resistant gene MDR-1 [26–28]. HCC is associated with upregulation of dihydropyrimidine dehydrogenase, and thus is potentially resistant to chemotherapies [29, 30]. With the development of novel gene therapies, there is an opportunity to evaluate these agents in unresectable HCC. In our study, the rates of PR plus SD were 69.5% in the group treated with multiple hepatic arterial injections of Ad-p53 and 5-FU through PCS after TACE and 65.2% in the group treated with repeated TACE. TTP and OS were 9.6 and 12.8 months in group 1; 8.3 and 10.4 months in group 2, respectively. Therefore, our results suggest that multiple hepatic arterial injections of Ad-p53 and 5-FU through PCS after TACE for unresectable HCC patients are well tolerated and could achieve response rates similar to those achieved with repeated TACE.

The p53 tumor suppressor gene is functionally inactivated in about 50% of all human malignancies including up to 61% of HCC [11, 12]. Some research has been done and found that high expression of p53 *in vivo* may exert therapeutic effects on HCC in two aspects: (i) high expression of exogenous p53 protein induces apoptosis of tumor cells through several biological pathways [31–33] and (ii) exogenous p53 renders HCC more sensitive to some chemotherapeutic agents [34]. It is reported that wild-type p53 gene transfection increased the sensitivity of acquired 5-FU-resistant HCC cells to 5-FU [35]. We hypothesized that Ad-p53 and 5-FU have a synergetic effect in the therapy of HCC.

Many Ad-p53 gene therapy studies have been performed previously in patients with incurable cancer. As the adenovirus applied in these trials did not allow selective tumor targeting, direct approaches of tumor targeting were applied. The safety and feasibility of intratumoral injection and body cavities infusion of Ad-p53 were established in patients with different types of cancer. The tumor-targeting approaches applied in these trials include administration of Ad-p53 by the use of CT-guided percutaneous fine-needle injection or bronchoscopy in patients with lung cancer [21, 22, 36], by gastroscopes in patients with esophageal carcinoma [37], and by intraperitoneal catheter in patients with epithelial ovarian cancer [38]. Evidence for transgene expression, and possibly induction of apoptosis, was documented by these trials. Multicentric occurrence and intrahepatic micrometastases frequently happen in patients with HCC. Intratumoral vector injection can only be applied to a limited number of visible lesions per patient. Effective organ-targeting approaches for HCC gene therapy are immediately required. On account of high immunogenicity and the high prevalence of crossreacting antibodies of adenovirus vectors, studies of Ad-p53 administered by hepatic arterial injections or intravenously were not carried out until recent years [25, 39]. The results show that Ad-p53 administered by hepatic arterial injections or intravenously were feasible and well tolerated. Furthermore, evidence of

tumorspecific apoptosis induced by elevated nuclear p53 protein expression was provided by the trial of intrahepatic arterial administration of Ad-p53 in patients with primarily colorectal cancer metastatic to the liver [25]. PCS was used as a liver-targeting approach in this study, which allows delivering drugs to every lesion, even minute lesions that cannot be detected by CT or B-mode ultrasound in the liver, and minimizing systemic toxicity. This approach also allows ambulatory treatment and avoids repetitive arterial access.

Despite the presence of neutralizing antibodies for adenovirus, we found that p53 transgene expression was detected in patients throughout the period of treatment. In addition, quantitative real-time RT-PCR analysis showed that the expression patterns of apoptosis-related p53-targeted genes such as p21 and p53AIP1 paralleled that of exogenous p53 (Fig. 3), demonstrating that exogenous p53 produced after Ad-p53 treatment has biological activity. These findings further demonstrate that circulating neutralizing anti-Ad antibodies do not inhibit vector-mediated transgene expression when Ad-p53 is injected into the hepatic artery.

Fever was observed as the most common Ad-p53/5-FU treatment-related side effect, which could be because of the transient systemic spread of the vector itself. Transient fever has been previously reported as an adverse event after intravenous administration of Ad-p53 in patients with advanced cancer [39], and this finding was similar to our study.

The blood supply to liver cancer comes through the hepatic artery and portal vein. The portal vein plays an important role in the blood supply to less-blood-supply liver cancer, small liver cancer, satellite nodular, portal vein tumor thrombus, and surrounding area and membrane of big liver cancer. That may account for the modest antitumor activity in some patients of this study. It will be more promising if the drug is dually delivered through the hepatic artery and portal vein.

Preclinical data accumulated in recent years suggest that the combination of gene therapy and other methods of treatment, specifically, chemotherapy, might provide significant benefits for the treatment of HCC [40]. Here, we provide direct clinical evidence in support of this emerging paradigm in HCC gene therapy. The clinical activity of this combination deserves further investigation in large-scale trials. Cancer gene therapy may be most effective not as a single modality but rather in close combination with other methods of treatment. This concept may have broad implications for the further development of new gene therapy strategies.

Acknowledgements

This study was funded in part by Science and Technology Grants for Medicine and Health Research from the Shenzhen Bureau of Science, Technology and Information, grant number 04029.

References

- 1 Parkin DM, Bray F, Ferlay J, Pisani P. Estimating the world cancer burden: globocan 2000. *Int J Cancer* 2001; 94:153–156.
- 2 Chen JG, Zhu J, Parkin DM, Zhang YH, Lu JH, Zhu YR, Chen TY. Trends in the incidence of cancer in Qidong, China, 1978–2002. *Int J Cancer* 2006; 119:1447–1454.
- 3 El-Serag HB, Rudolph KL. Hepatocellular carcinoma: epidemiology and molecular carcinogenesis. *Gastroenterology* 2007; 132:2557–2576.
- 4 Anzola M. Hepatocellular carcinoma: role of hepatitis B and hepatitis C viruses proteins in hepatocarcinogenesis. *J Viral Hepat* 2004; 11: 383–393.
- 5 Wang XW, Gibson MK, Vermeulen W, Yeh H, Forrester K, Sturzbecher HW, et al. Abrogation of p53-induced apoptosis by the hepatitis B virus X gene. *Cancer* 1995; 55:6012–6016.
- 6 Williams R, White J, Croce M, Dilawari R. Surgical options in the treatment of hepatocellular carcinoma. *Am Surg* 2007; 73:58–62.
- 7 Alsowmely AM, Hodgson HJ. Non-surgical treatment of hepatocellular carcinoma. *Aliment Pharmacol Ther* 2002; 16:1–15.
- 8 Biselli M, Andreone P, Gramenzi A, Trevisani F, Cursaro C, Rossi C, et al. Transcatheter arterial chemoembolization therapy for patients with hepatocellular carcinoma: a case controlled study. *Clin Gastroenterol Hepat* 2005; 3:918–925.
- 9 Weinberg RA. Tumour suppressor genes. *Science* 1991; 254:1138–1146.
- 10 Bishop JM. The molecular genetics of cancer. *Science* 1987; 235:305–311.
- 11 Hsia CC, Nakashima Y, Thorgeirsson SS, Harris CC, Minemura M, Momosaki S, et al. Correlation of immunohistochemical staining and mutations of p53 in human hepatocellular carcinoma. *Oncol Rep* 2000; 7:353–356. *394 Anti-Cancer Drugs* 2009, Vol 20 No 5
- 12 Honda K, Sbisà E, Tullo A, Papeo PA, Saccone C, Poole S, et al. p53 mutation is a poor prognostic indicator for survival in patients with hepatocellular carcinoma undergoing surgical tumour ablation. *Br J Cancer* 1998; 77:776–782.
- 13 Levine AJ. p53, the cellular gatekeeper for growth and division. *Cell* 1997; 88:323–331.
- 14 Lowe SW, Ruley HE, Jacks T, Housman DE. p53-dependent apoptosis modulates the cytotoxicity of anticancer agents. *Cell* 1993; 74:957–967.
- 15 Eisold S, Linnebacher M, Ryschich E, Antolovic D, Hinz U, Klar E, Schmidt J. The effect of adenovirus expressing wild-type p53 on 5-fluorouracil chemosensitivity is related to p53 status in pancreatic cancer cell lines. *World J Gastroenterol* 2004; 10:3583–3589.
- 16 Nielsen LL, Gurnani M, Syed J, Dell J, Hartman B, Cartwright M, Johnson RC. Recombinant E1-deleted adenovirus-mediated gene therapy for cancer: efficacy studies with p53 tumor suppressor gene and liver histology in tumor xenograft models. *Hum Gene Ther* 1998; 9:681–694.
- 17 Rakkar ANS, Katayose Y, Kim M, Craig C, Choi YH, Lee SH, et al. A novel adenoviral vector expressing human Fas/CD95/APO-1 enhances p53-mediated apoptosis. *Cell Death Diff* 1999; 6:326–333.

- 18 Waku T, Fujiwara T, Shao J, Itoshima T, Murakami T, Kataoka M, et al. Contribution of CD95 ligand-induced neutrophil infiltration to the bystander effect in p53 gene therapy for human cancer. *J Immunol* 2000; 165:5884–5890.
- 19 Clayman GL, el-Naggar AK, Lippman SM, Henderson YC, Frederick M, Merritt JA, et al. Adenovirus-mediated p53 gene transfer in patients with advanced recurrent head and neck squamous cell carcinoma. *J Clin Oncol* 1998; 16:2221–2232.
- 20 Lang FF, Bruner JM, Fuller GN, Aldape K, Prados MD, Chang S, et al. Phase I trial of adenovirus-mediated p53 gene therapy for recurrent glioma: biological and clinical results. *J Clin Oncol* 2003; 21:2508–2518.
- 21 Nemunaitis J, Swisher SG, Timmons T, Connors D, Mach M, Doerksen L, et al. Adenovirus-mediated p53 gene transfer in sequence with cisplatin to tumors of patients with non-small-cell lung cancer. *J Clin Oncol* 2000; 18:609–622.
- 22 Swisher SG, Roth JA, Komaki R, Gu J, Lee JJ, Hicks M, et al. Induction of p53-regulated genes and tumor regression in lung cancer patients after intratumoral delivery of adenoviral p53 (INGN 201) and radiation therapy. *Clin Cancer Res* 2003; 9:93–10E1.
- 23 Guan YS, Sun L, Zhou XP, Li X, He Q, Liu Y. Combination therapy with recombinant adenovirus-p53 injection (rAd-p53) via transcatheter hepatic arterial chemoembolization for advanced hepatic carcinoma. *Shijie Huaren Xiaohua Zazhi* 2005; 13:125–127.
- 24 Reid T, Galanis E, Abbruzzese J, Sze D, Andrews J, Romel L, et al. Intra-arterial administration of a replication-selective adenovirus (dl1520) in patients with colorectal carcinoma metastatic to the liver: a phase I trial. *Gene Ther* 2001; 8:1618–1626.
- 25 Atencio IA, Grace M, Bordens R, Fritz M, Horowitz J A, Hutchins B, et al. Biological activities of a recombinant adenovirus p53 (SCH 58500) administered by hepatic arterial infusion in a Phase 1 colorectal cancer trial. *Cancer Gene Ther* 2006; 13:169–181.
- 26 Huang M, Liu G. The study of innate drug resistance of human hepatocellular carcinoma Bel7402 cell line. *Cancer Lett* 1999; 135:97–105.
- 27 Kato A, Miyazaki M, Ambiru S, Yoshitomi H, Ito H, Nakagawa K, et al. Multidrug resistance gene (MDR-1) expression as a useful prognostic factor in patients with human hepatocellular carcinoma after surgical resection. *J Surg Oncol* 2001; 78:110–115.
- 28 Kuo MT, Zhao JY, Teeter LD, Ikeguchi M, Chisari FV. Activation of multidrug resistance (Pglycoprotein) *mdr3/mdr1a* gene during the development of hepatocellular carcinoma in hepatitis B virus transgenic mice. *Cell Growth Differ* 1992; 3:531–540.
- 29 DeVita VT Jr, Abou-Alfa GK. Therapeutic implications of the new biology. *Cancer J Sci Am* 2000; 6 (Suppl 2):113–120.
- 30 Jiang W, Lu Z, He Y, Diasio RB. Dihydropyrimidine dehydrogenase activity in hepatocellular carcinoma: implication in 5-fluorouracil-based chemotherapy. *Clin Cancer Res* 1997; 3:395–399.

- 31 Schuler M, Bossy-Wetzel E, Goldstein JC, Fitzgerald P, Green DR. p53 induces apoptosis by caspase activation through mitochondrial cytochrome c release. *J Biol Chem* 2000; 275:7337–7342.
- 32 Soengas MS, Alarco'n RM, Yoshida H, Giaccia AJ, Hakem R, Mak TW, Lowe SW. Apaf-1 and caspase-9 in p53-dependent apoptosis and tumor inhibition. *Science* 1999; 284:156–159.
- 33 Muller M, Strand S, Hüg H, Heinemann EM, Walczak H, Hofmann WJ, et al. Drug-induced apoptosis in hepatoma cells is mediated by the CD95 (APO-1/Fas) receptor/ligand system and involves activation of wild-type p53. *J Clin Invest* 1997; 99:403–413.
- 34 Guo Y, Zeng Y, Wang K, Zhu X, Luo H, Zheng M, et al. Therapeutic potential of recombinant adenovirus expressing p53 in hepatocellular carcinoma cell lines. *Zhonghua Ganzangbing Zazhi* 2001; 9:43–45.
- 35 Li YX, Lin ZB, Tan HR. Wild type p53 increased chemosensitivity of drug-resistant human hepatocellular carcinoma Bel7402/5-FU cells. *Acta Pharmacol Sin* 2004; 25:76–82.
- 36 Swisher SG, Roth JA, Nemunaitis J, Lawrence DD, Kemp BL, Carrasco CH, et al. Adenovirus-mediated p53 gene transfer in advanced non-small-cell lung cancer. *J Natl Cancer Inst* 1999; 91:763–771.
- 37 Shimada H, Matsubara H, Shiratori T, Shimizu T, Miyazaki S, Okazumi S, et al. Phase I/II adenoviral p53 gene therapy for chemoradiation resistant advanced esophageal squamous cell carcinoma. *Cancer Sci* 2006; 97:554–561.
- 38 Buller RE, Runnebaum IB, Karlan BY, Horowitz JA, Shahin M, Buekers T, et al. A phase I/II trial of rAd/p53 (SCH 58500) gene replacement in recurrent ovarian cancer. *Cancer Gene Ther* 2002; 9:553–566.
- 39 Tolcher AW, Hao D, de Bono J, Miller A, Patnaik A, Hammond LA, et al. Phase I, pharmacokinetic, and pharmacodynamic study of intravenously administered Ad5CMV-p53, an adenoviral vector containing the wild-type p53 gene, in patients with advanced cancer. *J Clin Oncol* 2006; 24:2052–2058.
- 40 Guan YS, La Z, Yang L, He Q, Li P. p53 gene in treatment of hepatic carcinoma: status quo. *World J Gastroenterol* 2007; 13:985–992. p53 gene combination therapy for HCC Tian et al. 395